



Salmon oil supplementation in dogs affects the blood flow of testicular arteries

Marcelo Carvalho Santos¹ | Chiara Milani² | Paolo Zucchini² | Celia Raquel Quirino¹ | Stefano Romagnoli² | Isabel Candia Nunes da Cunha¹ 

¹Universidade Estadual do Norte Fluminense Darcy Ribeiro, Campos Dos Goytacazes, Brazil

²Department of Animal Medicine, Production and Health, University of Padova, Legnaro, Italy

Correspondence

Isabel Candia Nunes da Cunha, Universidade Estadual do Norte Fluminense Darcy Ribeiro, Campos Dos Goytacazes, RJ, Brazil. Email: cunhaicn@uenf.br

Funding information

Coordenação de Aperfeiçoamento de Pessoal de Nível Superior, Grant/Award Number: 88881.134613/2016-01

Abstract

The administration of fish oils is known to cause changes in several reproductive parameters of domestic animals. The ingestion of polyunsaturated fatty acids (PUFAs) of the omega-3 family, such as docosahexaenoic acid (DHA) and eicosapentaenoic acid (EPA), has been described and correlated with changes in the semen quality, testosterone levels and male fertility. Nevertheless, few studies monitored and registered effects after ceasing supplementation. In the present study, we monitored the Doppler velocimetric and ultrasonographic parameters of nine dogs' testis for 90 days (D90) checking the effect of salmon oil supplementation, and monitoring continued for 60 days more, after ceasing supplementation (D150). Ultrasonographic evaluations comprised determining the Doppler velocimetric parameters, testicular and epididymal volume, and testicular echotexture. Peak systolic velocity (PSV) as well as final diastolic velocity (EDV) in the suprastesticular arteries (STA), and marginal artery (MA) increased during the period of treatment and kept that level up to D150. There was no difference between the fish-oil supplementation period and the unsupplemented one regarding the testicular and epididymal volume and echogenicity and heterogeneity characteristics. A negative correlation was found between heterogeneity of testis and sperm production ($r = -.41$, $p = .008$). Doppler velocimetry indices were affected by the supplementation, leading to an increase in testicular blood flow.

KEYWORDS

Canine, echogenicity, echography, omega-3, polyunsaturated fatty acids, reproduction

1 | INTRODUCTION

Ultrasonography became one of the most significant advances in animal reproduction with the grey-scale and real-time dynamic imaging development at the start of the 1980s (Ginther, 2014). Nowadays, it is a critical complementary diagnostic method in different conditions for assessing the reproductive functions in males and females.

In recent years, Doppler ultrasound has allowed a better evaluation of reproductive organs, providing useful information on blood flow and speed in those organs (Barbosa et al., 2013; Freitas et al., 2015; Silva et al., 2015). Differences in testicular Doppler

velocimetry indices have been found between pre-pubertal and post-pubertal dogs (Souza, England, et al., 2015) and between fertile and infertile dogs (Souza, Barbosa, et al., 2015). Moxon et al. (2015) evaluated the testicular and prostatic echotexture and reported a relationship between echogenicity/heterogeneity and semen quality. In that study, the testicular echogenicity was negatively correlated with the percentage of morphologically normal live spermatozoa (more echogenic testes were associated with fewer normal sperm). Mean testicular heterogeneity was positively correlated with the total spermatozoal output (more heterogenous testes, being those with anechoic parenchyma and prominent echogenic stippling, were

associated with greater sperm output) but not with any other semen quality measure.

The ingestion of polyunsaturated fatty acids (PUFAs) from the omega-3 family, such as docosahexaenoic acid (DHA) and eicosapentaenoic acid (EPA), has been correlated with changes in the semen quality, testosterone levels and fertility in humans and dogs (Esmaeili et al., 2015; Ferramosca et al., 2017; Risso et al., 2015). In dogs, the administration of fish oil (FO) in the diet improved semen quality by increasing the percentage of motility and the typical morphology of sperm, and the total number of spermatozoa, and their overall vitality (Risso et al., 2015; Santos et al., 2019).

Testicular capillary pressure and oxygen tension are typically low, so spermatogenesis is adapted to a semi-hypoxic environment (Reyes et al., 2012), avoiding damages from oxygen free radicals to semen, especially spermatid DNA (Aitken, 1989; Max, 1992; Setchell & Breed, 2006). The use of PUFAs has been recommended to decrease the reactive oxygen species (ROS) damages in spermatogenesis and improve semen quality (Rocha et al., 2009; Santos et al., 2019).

The process of spermatogenesis is susceptible to reduced blood flow, and even minor reductions in testicular perfusion can affect semen production, particularly in the initial spermatogenesis stages (Bergh et al., 2001).

In humans, EPA and DHA dietary administrations have different protective and beneficial effects in the cardiovascular field, reducing blood pressure and cardiac frequency and improving vascular function (vascular reactivity) (Filipovic et al., 2018; Mori, 2014). The present study aimed to determine whether dietary supplementation with salmon oil can influence the testicular echostructure and vascular function by analysing Doppler velocimetric parameters of canine testicular arteries and follow the residual effects for 60 days after suspending supplementation.

2 | MATERIALS AND METHODS

2.1 | Animals and experimental design

The study was conducted in Padua, in northern Italy (coordinates: 45°24'23"N; 11°52'40"E), where the four seasons are well defined. The experiment began in October 2017 (fall) and ended in February 2018 (end of winter). The ethics committee from the Universidade Estadual do Norte Fluminense approved the study (CEUA-UENF protocol no. 393). The animal's inclusion criteria were as follows: (a) presented similar health status, (b) proven fertility, (c) must come from commercial kennels and (d) be trained and adapted to semen collection by manual manipulation. Nine dogs underwent detailed clinical examination and attended all inclusion criteria. Dogs were of different breeds: 04 Flat-Coated Retriever, 02 Australian Sheepdog, 01 Labrador, 01 Cocker Spaniel and 01 French Bulldog, with a weight between 23 and 38 kg and ages ranging from 2 to 8 years. The dogs remained with their owners during the entire study.

The health check and US evaluations were performed three times during the study: at the beginning of the experiment (day 0 = D0 = the control), at day 90 (D90) and at day 150 (D150), which was the end of the study. From D0 to D90, all dogs received salmon oil supplementation (Grizzly Salmon Oil, Grizzly Pet Products, LLC) at the dose recommended by the manufacturer, where each 3.5 ml of the product contained: Omega-3 – 935 mg; Omega-6 – 95 mg; DHA – 355 mg; and EPA – 320 mg. Supplementation provided a dosage of 180 mg DHA/7 kg bodyweight of the animal per day, supplied in liquid form and placed over the food. Grizzly Salmon Oil™ is derived only from wild Alaskan salmon, which spend their lives foraging their native nutrient-rich diet. The resulting oil contains a balanced blend of valuable fatty acids, inherent antioxidants and vitamins that inherently occur in the salmon, and it will not interfere with the pet's intake of vitamins from other sources. The choice for salmon oil was because of the high concentration of omega-3 present in the product compared to other types of fish oils (Calder, 2017). The animals were fed with the owners' feed of choice, as they used to do before the experimental period. The animals were fed twice a day.

2.2 | Ultrasonography

Ultrasound evaluations were performed with a Philips Affiniti 50 apparatus (Philips SpA) equipped with a multi-frequency linear transducer with an operating range of 5–18 MHz. Dogs were restrained on the right lateral recumbency, and the transducer was placed on the scrotum after the application of ultrasound gel. B-mode ultrasound was used to assess testicular echogenicity, homogeneity, heterogeneity and volume. A longitudinal (using the mediastinum as a reference point) and a transversal plane were used to determine testicular length and height and testicular width. Testicular volume was determined using the ellipsoid formula: length (L) × width (W) × height (H) × 0.5236 (Paltiel et al., 2002).

In the Doppler velocimetry evaluation, the duplex mode was used to visualize the testicular arteries of both testes, comprising three branches: suprastesticular artery (STA), marginal artery (MA), and intrastesticular arteries (ITA). Blood vessels and the corresponding flows were red (blood flowing towards the transducer) and blue (blood flowing away from the transducer) in the left and right testes. Pulsed Doppler evaluation was performed after locating the main testicular artery. The Doppler gate (size of the sample volume) was placed on the vessel lumen, and the arterial blood flows were graphically represented as waves. Three waves were chosen and measured, and the following Doppler velocimetric parameters were estimated: peak systolic velocity (PSV), end-diastolic velocity (EDV), resistance index (RI), and pulsatility index (PI). The RI and PI were calculated and recorded automatically by the ultrasound machine: $RI = (PSV - EDV / PSV)$; $PI = (PSV - EDV / M)$, where M is the mean between PSV and EDV (Middleton et al., 1989). The sample size (gate) was 2/3 the size of the vessel. The angle of insonation was smaller than 60°, and the same

operator performed each examination. The pulse repetition frequency (PRF) was adjusted for the visualization of the smaller calibre vessels.

2.3 | Measurement of echogenicity and homogeneity

Digitized images of the testes in transversal and longitudinal sections were used for the measurements, using the ImageJ software (National Institutes of Health, Bethesda, Maryland; <http://rsb.info.nih.gov/ij/>), where the values were expressed in the intensity of pixels (PIx). To measure the testes' echogenicity, two reference points (one dorsal and the other ventral concerning the testicular mediastinum) were chosen in the hyperechogenic capsule (*tunica albuginea*) of the testes. Each point (in the longitudinal testis plane) selected had dimensions of $2.0 \times 0.5 \text{ mm}^2$, always having the testicular mediastinum as reference. Ten other regions were chosen randomly in the testicular parenchyma (each square with 2.0 mm^2), avoiding the central mediastinum. The echogenicity of the region of interest was calculated according to the following formula: echogenicity percentage = (mean PIx of the capsule/mean PIx of the testicular parenchyma) \times 100 (Moxon et al., 2015). The testicular heterogeneity was calculated as the SD of the mean echogenicity. According to this method, low values (low variation between regions of interest) represent more homogeneous tissues, while high values (high variation between the regions of interest) denote less homogeneous tissues. For this step, the data were tallied by two independent operators.

2.4 | Statistical analysis

Descriptive statistic calculations, consistency tests and regular data distribution were performed with the GLM procedure, followed by the variance (SAS 9.4 version, 2019; SAS Institute Inc.). The testing day was the fixed effect, and each animal was considered a repeated effect. The SNK test compared the means at 5% significance ($p < .05$). The echogenicity/heterogeneity, the testicular size and blood flow indices were tested using the Pearson linear correlation analysis at each time point (D0, D90, D150).

3 | RESULTS

The Doppler ultrasonography revealed that the wave of the three artery measures' spectral shape was monophasic, with systolic peaks, continuous diastolic flow and low vascular resistance. Table 1 presents the variables PSV, EDV, RI and PI of the nine animals during the study period. There was a significant difference at D90 for the parameter PSV of the suprastesticular artery in both testes (Figure 1 and Figure 2), maintaining the higher level until D150. In contrast, the PSV of the marginal artery increased on D90 in both testes and then declined in both testes, with mean values of D150 statistically

similar to those of D0. Further, regarding the marginal artery, there was an increase of the EDV on D90 for both testes, after which the value for the left testis measured on D150 declined, while that of the right testis remained the same as on D90 (Figure 1 and Figure 2). No significant differences were found in the RI and PI of the STA, MA and ITA. Also, no significant differences were observed for the Doppler velocimetric parameters between the right and left testis during the experiment, and no blood flow was detected with the use of the Doppler technique in the epididymis's tail.

Table 2 summarizes the echogenicity and testicular heterogeneity values, along with the testes' volume (right and left) and epididymis tail (right and left) of the eight dogs during the 150 days of the experiment. None of the values found showed statistically significant differences.

There was a negative correlation between sperm heterogeneity and concentration ($r = -.41$; $p = .008$). There were no significant correlations between serum testosterone levels and the testicular size, echogenicity or blood flow indices.

4 | DISCUSSION

In this study, we assessed the echogenicity of canine testicular parenchyma by measuring pixel intensity in various regions (excluding the testicular mediastinum) compared with an anatomically consistent echogenic reference point proposed by Moxon et al. (2015), since the tunica albuginea echogenicity does not change. We conclude that this method has advantages compared to the simple measurement of pixel intensity performed by other researchers (Dias et al., 2017; Oliveira Pinho et al., 2013; Tomlinson et al., 2017).

It is essential to mention that the heterogeneity was measured by pixel intensity variation within small sample areas so that the tests involving less echogenic parenchyma showed high heterogeneity. Presumably, the focal regions with higher homogeneity reflect higher density, which might show a larger number of cells undergoing spermatogenesis (Giffin et al., 2014), and more outstanding sperm production. Camela et al. (2018) documented testicular echotexture differences in sheep with pre-pubertal animals showing higher heterogeneity than post-pubertal animals because of the various testicular histomorphology changes occurring after puberty, especially in the proliferative post-mitotic phase of the cells forming the seminiferous tubules. The decrease in heterogeneity and sperm concentration increase is probably related to the rise in serum testosterone levels caused by omega-3 supplementation (Santos et al., 2019).

England et al. (2017) found a relationship between testicular echogenicity and progressive motility of canine spermatozoa. Moxon et al. (2015) showed that mean testicular heterogeneity was positively correlated with the total spermatozoal output. However, other researchers did not find a correlation between pixel intensity and sperm production or semen quality in dogs (Dias et al., 2017; Pinho et al., 2012; Tomlinson et al., 2017). Many researchers have reported that testicular echogenicity increases during sexual development directly with seminiferous

Parameter	D0	D90	D150	p-value
Right testis				
Supratesticular artery				
PSV (cm/s)	9.34 ± 2.37 ^b	15.21 ± 5.45 ^a	16.24 ± 3.32 ^a	.01
EDV (cm/s)	4.88 ± 1.44	5.84 ± 1.45	6.01 ± 1.07	.23
RI	0.46 ± 0.12	0.59 ± 0.14	0.63 ± 0.07	.08
PI	0.75 ± 0.31	1.06 ± 0.53	1.10 ± 0.28	.14
Marginal artery				
PSV (cm/s)	8.81 ± 3.50 ^b	12.70 ± 3.40 ^a	11.27 ± 3.79 ^a	.04
EDV (cm/s)	4.91 ± 2.16 ^b	7.56 ± 2.14 ^a	7.25 ± 3.18 ^a	.05
RI	0.45 ± 0.07	0.39 ± 0.18	0.37 ± 0.10	.39
PI	0.62 ± 0.14	0.59 ± 0.31	0.55 ± 0.18	.80
Intratesticular artery				
PSV (cm/s)	6.70 ± 3.77	5.64 ± 0.91	6.17 ± 2.02	.41
EDV (cm/s)	3.35 ± 2.04	3.670.83	3.71 ± 0.92	.97
RI	0.49 ± 0.14	0.42 ± 0.10	0.38 ± 0.12	.17
PI	0.88 ± 0.41	0.63 ± 0.27	0.54 ± 0.23	.11
Left testis				
Supratesticular artery				
PSV (cm/s)	10.03 ± 4.05 ^b	15.76 ± 5.43 ^a	14.84 ± 3.12 ^a	.01
EDV (cm/s)	6.00 ± 3.36	5.90 ± 2.40	6.70 ± 1.61	.87
RI	0.46 ± 0.23	0.62 ± 0.10	0.53 ± 0.15	.75
PI	0.82 ± 0.41	1.16 ± 0.36	0.85 ± 0.41	.29
Marginal artery				
PSV (cm/s)	7.41 ± 2.72 ^b	14.53 ± 7.95 ^a	8.84 ± 2.66 ^b	.01
EDV (cm/s)	4.50 ± 1.86 ^b	7.20 ± 2.20 ^a	5.12 ± 2.64 ^b	.02
RI	0.40 ± 0.17	0.46 ± 0.13	0.44 ± 0.13	.38
PI	0.67 ± 0.16	0.71 ± 0.35	0.87 ± 0.61	.86
Intratesticular artery				
PSV (cm/s)	5.87 ± 3.66	5.54 ± 2.31	5.85 ± 1.93	.81
EDV (cm/s)	3.36 ± 1.39	3.01 ± 1.26	3.62 ± 0.83	.57
RI	0.38 ± 0.18	0.46 ± 0.07	0.36 ± 0.09	.21
PI	0.67 ± 0.26	0.76 ± 0.23	0.63 ± 0.26	.50

Note: Different lowercase letters in the row (a, b) indicate significant differences between the periods (D0, D90, and D150) ($p \leq .05$).

tubules growth (Camela et al., 2018; Hamm & Fobbe, 1995; Pozor et al., 2017; Silva et al., 2012). It is plausible that increased or decreased testicular echogenicity represents ultrastructural changes within the testes associated with altered sperm morphology (Santos et al., 2019).

An important observation regarding the clinical use of quantitative measurements of pixel intensity is that such measurements should be performed at the testicular parenchyma level, increasing the parenchyma homogeneity's evaluation precision. Testicles showing a general heterogeneous appearance, with irregular and diffuse echogenic structures within the parenchyma, are frequently characterized by low sperm production (Vencato et al., 2014).

Although we evaluated animals of different weights and sizes, testicular volume did not differ between left and right testes, as also

TABLE 1 Mean ± SD of Doppler velocimetry indices [peak systolic velocity (PSV), end-diastolic velocity (EDV), resistance index (RI) and pulsatility index (PI)] of the supratesticular, marginal and intratesticular arteries of the right and left testes of 9 adult dogs submitted to oral supplementation with salmon oil for 90 days (D0–D90) and after supplementation (D90–D150)

reported by other authors (England, 1991; Moxon et al., 2015; Pugh et al., 1990; Souza, England, et al., 2015), but in contrast to the study of Souza, Mota Filho, et al. (2014). There were also no significant differences between the epididymal tail volume during the experiment, in agreement with Moxon et al. (2015). Concerning the testis size and weights, we found that scrotal width was strongly correlated with testicular weight and provided a convenient testicular size and potential sperm production index (Santos et al., 2019).

In colour Doppler images, the testicular arteries investigated in this study showed an anatomical pattern similar to that described in dogs by other authors (Gumbsch et al., 2002; Günzel-Apel et al., 2001; Souza, Da Cunha Barbosa, et al., 2014), in which the artery of the spermatic cord had a tortuous profile, and the marginal artery had a more linear course, following the curvature from

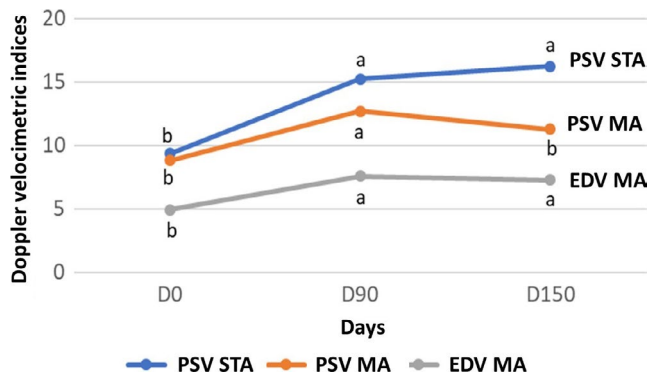


FIGURE 1 Effect of supplementation with salmon oil in nine adult dogs on the PSV (peak systolic velocity) and EDV (end-diastolic velocity) values of the suprastesticular artery (STA) and marginal artery (MA) of the right testicle during 150 days

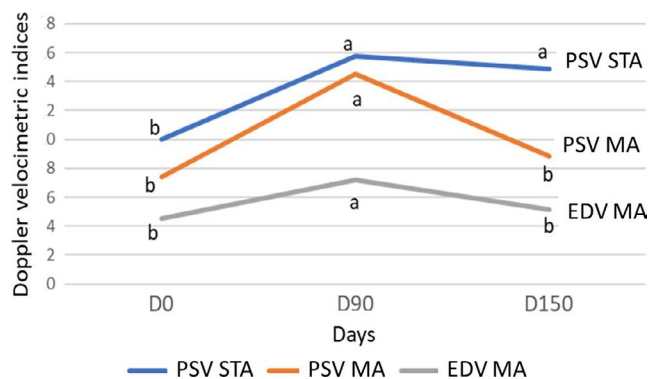


FIGURE 2 Effect of supplementation with salmon oil in nine adult dogs on the PSV (peak systolic velocity) and EDV (end-diastolic velocity) values of the suprastesticular artery (STA) and marginal artery (MA) of the right testicle during 150 days

the cranial to caudal testicular pole. Similar results were reported in stallions (Pozor & McDonnell, 2004). In the Doppler spectral images, the testicular arteries exhibited a pattern similar to that described in humans (Middleton et al., 1989) and dogs (Carrillo et al., 2012; Gumbsch et al., 2002; Souza, Da Cunha Barbosa, et al., 2014), in which the waves measured in the spermatic cord and marginal location to the testes and intratesticular arteries exhibited a non-resistant wave pattern. Different results were reported in stallions, where there was a resistant wave pattern in the spermatic cord (Pozor & McDonnell, 2004).

No significant differences were detected in the Doppler velocimetry indices between the right and left testes of the dogs of our study, in agreement with the findings of England et al. (2017) but disagreeing with those of Souza, Mota Filho, et al. (2014). This disagreement is probably related to the accuracy of the site assessed in the sperm cord, as several measurement sites can provide different results (Trautwein et al., 2020).

The values found for the Doppler velocimetric indices of the arteries (STA, MA, and ITA) like those observed in the present study were also reported by Trautwein et al. (2020), England et al. (2017) and Carrillo et al. (2012). Günzel-Apel et al. (2001) reported that the intratesticular veins were not suitable to measure blood flow by pulsed Doppler ultrasonography, although, in the present study, it was possible to detect the intratesticular arteries in all the examinations. However, Gumbsch et al. (2002) did not find the intratesticular vessels in 41.5% of the cases.

It is noteworthy that most of the Doppler velocimetric values of the suprastesticular and marginal arteries, as shown in Figure 1 and Figure 2, were ascending, that is they were initially (D0) low and then increased after the treatment (D90) and remained at the higher level until the end of the experiment (D150). A fluctuation of arterial pressure during the day explains this behaviour. However,

TABLE 2 Mean \pm SD of testicular echogenicity, heterogeneity, and volume and epididymis tail volume of the right and left testes of nine dogs submitted to oral supplementation with salmon oil for 90 days (D0–D90) and after supplementation (D90–D150)

Characteristics	D0	D90	D150	p-value
Echogenicity of right testicle (%)	226.75 \pm 36.01	224.15 \pm 34.57	194.87 \pm 13.40	.86
Echogenicity of left testicle (%)	233.15 \pm 35.20	237.18 \pm 45.62	214.12 \pm 26.16	.82
Heterogeneity of right testicle (%)	12.92 \pm 2.21	12.47 \pm 1.25	11.44 \pm 1.45	.57
Heterogeneity of left testicle (%)	12.52 \pm 0.64	12.67 \pm 1.34	11.83 \pm 1.37	.32
Volume of right testicle (cm ³)	10.08 \pm 3.29	11.19 \pm 3.83	9.96 \pm 4.99	.57
Volume of left testicle (cm ³)	11.03 \pm 4.39	12.68 \pm 5.57	9.96 \pm 4.60	.48
Volume of right epididymis tail (cm ³)	0.58 \pm 0.23	0.97 \pm 0.46	1.04 \pm 0.53	.69
Volume of left epididymis tail (cm ³)	0.49 \pm 0.34	0.68 \pm 0.32	0.79 \pm 40.40	.22

Miyazaki et al. (2002) observed that the circadian cycle in dogs varies little in 24 hr, probably because of the short sleeping-waking cycles and higher arterial pressure and cardiac frequency parameters near feeding time. All the dogs in our study were evaluated at the same time of day (morning), excluding the circadian rhythm effect (Piccione et al., 2005).

It has been shown that the ingestion of PUFAs, especially DHA, causes alterations in the blood flow patterns (Casanova et al., 2017; Fischer & Gleis, 2015; Singh et al., 2016), reducing molecule adhesion on the vascular endothelium (Huang et al., 2015), decreasing inflammatory substances, such as interleukin type 1 (IL-1) (Alfaidi et al., 2018), causing lower arterial pressure in hypertensive humans. We conclude that supplementation of PUFAs with omega-3 can improve the flow-mediated dilation, a measure of systemic endothelial function (Wang et al., 2012; Xin et al., 2012) since a healthy endothelium is vital to maintain blood circulation; and modulate the fluidity, vascular tonus and integrity of the blood vessels, by producing and secreting many vasoactive compounds like nitric oxide (Sinn & Howe, 2008). Various authors have reported vasodilator effects and improved cerebral blood perfusion correlated with the use of omega-3 by humans (Kuszewski et al., 2017; Schwarz et al., 2018). However, we found no study on the action of omega-3 in testicular blood perfusion in dogs.

The EPA and DHA, which have vasoprotective benefits, include decreased arterial plaque build-up, increased anti-inflammatory properties, improved endothelial-dependent vasodilation and decreased blood pressure, and increased antioxidant capacity (Zehr & Walker, 2018). In our experiment, the salmon oil administration affected the flow-mediated dilation, as shown by the increase in the Doppler velocimetry indices, which improved the testicular endothelial function. This effect lasted 2 months after the supplementation. The dog could be a model to study similar effects of salmon oil supplementation in men.

5 | CONCLUSION

The PSV and EDV parameters of the suprastesticular and marginal arteries were affected by the dietary supplementation, increasing their blood flows. Echotextural evaluation of the normal testis has a diagnosis and prognostic potential to sperm quality, mainly when performed sequentially. Testicular and epididymal volumes were not affected by salmon oil supplementation. Doppler analysis of the testis may be useful as an additional tool for the andrological examination of dogs. These findings must be viewed as preliminary and should be replicated in an independent experimental setting.

ACKNOWLEDGEMENTS

We thank the company Grizzly Pet Products for supplying the salmon oil, the University of Padua, and CAPES/PDSE (Grant 88881.134613/2016-01).

CONFLICT OF INTEREST

None of the authors have any conflict of interest to declare.

AUTHOR CONTRIBUTIONS

1. Marcelo Carvalho dos Santos. Doctoral thesis, (a) substantial contributions to conception and design, acquisition of data, analysis and interpretation of data, (b) drafting the article (c) revising manuscript critically for important intellectual content and (d) final approval of the version to be published.
2. Chiara Milani. (a) Substantial contributions acquisition of data, analysis and interpretation of data, (b) revising manuscript critically and (c) final approval of the version to be published.
3. Paolo Zucchini. (a) Substantial contributions acquisition of data.
4. Celia Raquel Quirino. (a) Substantial contributions analysis and interpretation of data.
5. Stefano Romagnoli. Doctoral thesis co-supervisor. (a) Substantial contributions to conception and design, analysis and interpretation of data and (b) revising manuscript critically for important intellectual content and (c) final approval of the version to be published.
6. Isabel Candia Nunes da Cunha. Doctoral thesis supervisor. (a) Substantial contributions to conception and design, acquisition of data, analysis and interpretation of data, (b) revising manuscript critically for important intellectual content and (c) final approval of the version to be published.

DATA AVAILABILITY

The data that support the findings of this study are available from the corresponding author upon reasonable request.

ORCID

Isabel Candia Nunes da Cunha  <https://orcid.org/0000-0002-6261-7431>

REFERENCES

- Alfaidi, M. A., Chamberlain, J., Rothman, A., Crossman, D., Villa-Uriol, M. C., Hadoke, P., Wu, J., Schenkel, T., Evans, P. C., & Francis, S. E. (2018). Dietary docosahexaenoic acid reduces oscillatory wall shear stress, atherosclerosis, and hypertension, most likely mediated via an IL-1-mediated mechanism. *Journal of the American Heart Association*, 7(13), 1–16. <https://doi.org/10.1161/JAHA.118.008757>
- Barbosa, C. D. C., Souza, M. B. D., Freitas, L. A. D., Silva, T. F. P. D., Domingues, S. F. S., & Silva, L. D. M. D. (2013). Assessment of uterine involution in bitches using B-mode and Doppler ultrasonography. *Animal Reproduction Science*, 139(1–4), 121–126. <https://doi.org/10.1016/j.anireprosci.2013.02.027>
- Bergh, A., Collin, O., & Lissbrant, E. (2001). Effects of acute graded reductions in testicular blood flow on testicular morphology in the adult rat. *Biology of Reproduction*, 64(April), 13–20. <https://doi.org/10.1095/biolreprod64.1.13>
- Calder, P. C. (2017). Omega-3: The good oil. *Nutrition Bulletin*, 42(2), 132–140. <https://doi.org/10.1111/nbu.12261>
- Camela, E. S. C., Nociti, R. P., Santos, V. J. C., Macente, B. I., Murawski, M., Vicente, W. R. R., Bartlewski, P. M., & Oliveira, M. E. F. (2018). Changes in testicular size, echotexture, and arterial blood flow associated with the attainment of puberty in Dorper rams raised in a subtropical climate. *Reproduction in Domestic Animals*, 54(2), 131–137. <https://doi.org/10.1111/rda.13213>

- Carrillo, J. D., Soler, M., Lucas, X., & Agut, A. (2012). Colour and pulsed Doppler ultrasonographic study of the canine testis. *Reproduction in Domestic Animals*, 47(4), 655–659. <https://doi.org/10.1111/j.1439-0531.2011.01937.x>
- Casanova, M. A., Medeiros, F., Trindade, M., Cohen, C., Oigman, W., & Neves, M. F. (2017). Omega-3 fatty acids supplementation improves endothelial function and arterial stiffness in hypertensive patients with hypertriglyceridemia and high cardiovascular risk. *Journal of the American Society of Hypertension*, 11(1), 10–19. <https://doi.org/10.1016/j.jash.2016.10.004>
- da Silva, F. B., da Silva Lima, A. E., da Costa Neto, J. M., Costa, A. C. F., da Silveira, C. P. B., Mello, S. B., Lorangeira, D. F., & Oria, A. P. (2012). Utilização Do Aglepristone No Tratamento Da Hiperplasia Fibroepitelial Mamária Felina. *Veterinária E Zootecnia*, 19(3), 399–406.
- Dias, W., Faria, F. J. C., Fernandes, C. A. C., Sampaio, B. F. B., Santos, M. D., Rodrigues, W. B., Silva, J. C. B., & Costa, D. S. (2017). Testicular echotexture is not a viable method to indirectly evaluate the spermatogenic parameters in Nelore bulls. *Austral Journal of Veterinary Sciences*, 51, 45–51. <https://doi.org/10.4067/S0719-813220170001000045>
- England, G. C. W. (1991). Relationship between ultrasonographic appearance, testicular size, spermatozoal output and testicular lesions in the dog. *Journal of Small Animal Practice*, 32(6), 306–311. <https://doi.org/10.1111/j.1748-5827.1991.tb00936.x>
- England, G. C. W., Bright, L., Pritchard, B., Bowen, I. M., de Souza, M. B., Silva, L. D. M., & Moxon, R. (2017). Canine reproductive ultrasound examination for predicting future sperm quality. *Reproduction in Domestic Animals*, 52(2005), 202–207. <https://doi.org/10.1111/rda.12825>
- Esmaeili, V., Shahverdi, A. H., Moghadasian, M. H., & Alizadeh, A. R. (2015). Dietary fatty acids affect semen quality: A review. *Andrology*, 3(3), 450–461. <https://doi.org/10.1111/andr.12024>
- Ferramosca, A., Moscatelli, N., Di Giacomo, M., & Zara, V. (2017). Dietary fatty acids influence sperm quality and function. *Andrology*, 5(3), 423–430. <https://doi.org/10.1111/andr.12348>
- Filipovic, M. G., Aeschbacher, S., Reiner, M. F., Stivala, S., Gobatto, S., Bonetti, N., Risch, M., Risch, L., Camici, G. G., Luescher, T. F., Von Schacky, C., Conen, D., & Beer, J. H. (2018). Whole blood omega-3 fatty acid concentrations are inversely associated with blood pressure in young, healthy adults. *Journal of Hypertension*, 36(7), 1548–1554. <https://doi.org/10.1097/HJH.0000000000001728>
- Fischer, S., & Gleis, M. (2015). Health aspects of regular consumption of fish and omega-3-fatty acids. *Ernahrungs Umschau*, 62(9), 140–151. <https://doi.org/10.4455/eu.2015.026>
- Freitas, L. A., Pinto, J. N., Silva, H. V. R., & da Silva, L. D. M. (2015). Two-dimensional and Doppler sonographic prostatic appearance of sexually intact French Bulldogs. *Theriogenology*, 83(7), 1140–1146. <https://doi.org/10.1016/j.theriogenology.2014.12.016>
- Giffin, J. L., Bartlewski, P. M., & Hahnel, A. C. (2014). Correlations among ultrasonographic and microscopic characteristics of prepubescent ram lamb testes. *Experimental Biology and Medicine*, 239(12), 1606–1618. <https://doi.org/10.1177/1535370214543063>
- Ginther, O. J. (2014). How ultrasound technologies have expanded and revolutionized research in reproduction in large animals. *Theriogenology*, 81(1), 112–125. <https://doi.org/10.1016/j.theriogenology.2013.09.007>
- Gumbusch, P., Gabler, C., & Holzmann, A. (2002). Colour-coded duplex sonography of the testes of dogs. *Veterinary Record*, 151(5), 140–144. <https://doi.org/10.1136/vr.151.5.140>
- Günzel-Apel, A. R., Möhrke, C., & Poulsen Nautrup, C. (2001). Colour-coded and pulsed Doppler sonography of the canine testis, epididymis and prostate gland: Physiological and pathological findings. *Reproduction in Domestic Animals = zuchtthygiene*, 36(5), 236–240. <https://doi.org/10.1046/j.1439-0531.2001.00288.x%0A>
- Hamm, B., & Fobbe, F. (1995). Maturation of the testis: Ultrasound evaluation. *Ultrasound in Medicine and Biology*, 21(2), 143–147. [https://doi.org/10.1016/S0301-5629\(94\)00088-3](https://doi.org/10.1016/S0301-5629(94)00088-3)
- Huang, C. Y., Sheu, W. H. H., & Chiang, A. N. (2015). Docosahexaenoic acid and eicosapentaenoic acid suppress adhesion molecule expression in human aortic endothelial cells via differential mechanisms. *Molecular Nutrition and Food Research*, 59(4), 751–762. <https://doi.org/10.1002/mnfr.201400687>
- John Aitken, R., Clarkson, J. S., & Fishel, S. (1989). Generation of reactive oxygen species, lipid peroxidation, and human sperm function. *Biology of Reproduction*, 41(1), 183–197. <https://doi.org/10.1095/biolreprod41.1.183>
- Kuszewski, J. C., Wong, R. H. X., & Howe, P. R. C. (2017). Effects of long-chain Omega-3 polyunsaturated fatty acids on endothelial vasodilator function and cognition – Are they interrelated? *Nutrients*, 9(5), 487. <https://doi.org/10.3390/nu9050487>
- Max, B. (1992). This and That: Hair pigments, the hypoxic basis of life and the Virgilian journey of the spermatozoon. *Trends in Pharmacological Sciences*, 13(C), 272–276. [https://doi.org/10.1016/0165-6147\(92\)90084-J](https://doi.org/10.1016/0165-6147(92)90084-J)
- Middleton, W. D., Thorne, D. A., & Melson, G. L. (1989). Color Doppler ultrasound of the normal testis. *American Journal of Roentgenology*, 152(2), 293–297. <https://doi.org/10.2214/ajr.152.2.293>
- Miyazaki, H., Yoshida, M., Samura, K., Matsumoto, H., Ikemoto, F., & Tagawa, M. (2002). Ranges of diurnal variation and the pattern of body temperature, blood pressure and heart rate in laboratory beagle dogs. *Experimental Animals*, 51(1), 95–98. <https://doi.org/10.1538/expanim.51.95>
- Mori, T. A. (2014). Dietary n-3 PUFA and CVD: A review of the evidence. *Proceedings of the Nutrition Society*, 73(1), 57–64. <https://doi.org/10.1017/S0029665113003583>
- Moxon, R., Bright, L., Pritchard, B., Bowen, I. M., de Souza, M. B., da Silva, L. D. M., & England, G. C. W. (2015). Digital image analysis of testicular and prostatic ultrasonographic echogenicity and heterogeneity in dogs and the relation to semen quality. *Animal Reproduction Science*, 160, 112–119. <https://doi.org/10.1016/j.anireprosci.2015.07.012>
- Oliveira Pinho, R., Sampaio Costa, D., Siqueira, J. B., Martins, L. F., Chaya, A. Y., Neto, T. M., Eliza, S., Guimarães, F., & Guimarães, J. D. (2013). Correlation of sexual maturity stage with testicular echotexture in young Nelore Bulls. *Acta Scientiae Veterinariae*, 41(41), 1161.
- Paltiel, H. J., Diamond, D. A., Canzio, J. D., Zurakowski, D., Borer, J. G., & Atala, A. (2002). Testicular volume: Comparison of orchidometer and US measurements in dogs. *Radiology*, 22(11), 114–119. <https://doi.org/10.1148/radiol.2221001385>
- Piccione, G., Caola, G., & Refinetti, R. (2005). Daily rhythms of blood pressure, heart rate, and body temperature in fed and fasted male dogs. *Journal of Veterinary Medicine Series A: Physiology Pathology Clinical Medicine*, 52(8), 377–381. <https://doi.org/10.1111/j.1439-0442.2005.00758.x>
- Pinho, R. O., Costa, D. S., Siqueira, J. B., Chaya, A. Y., Neto, T. M., Martins, L. F., Guimarães, S. E. F., & Guimarães, J. D. (2012). Testicular echotexture and seminal quality of young Montana Tropical Compound bulls classified as sound and unsound for breeding. *Revista Brasileira De Zootecnia*, 41(8), 1961–1965. <https://doi.org/10.1590/S1516-35982012000800023>
- Pozor, M. A., & McDonnell, S. M. (2004). Color Doppler ultrasound evaluation of testicular blood flow in stallions. *Theriogenology*, 61(5), 799–810. [https://doi.org/10.1016/S0093-691X\(03\)00227-9](https://doi.org/10.1016/S0093-691X(03)00227-9)
- Pozor, M., Morrissey, H., Albanese, V., Khouzam, N., Deriberprey, A., Macpherson, M. L., & Kelleman, A. A. (2017). Theriogenology relationship between echotextural and histomorphometric characteristics of stallion testes. *Theriogenology*, 99, 134–145. <https://doi.org/10.1016/j.theriogenology.2017.05.031>

- Pugh, C. R., Konde, L. J., & Park, R. D. (1990). Testicular ultrasound in the normal dog. *Veterinary Radiology*, 31(4), 195–199. <https://doi.org/10.1111/j.1740-8261.1990.tb01810.x>
- Reyes, J. G., Farias, J. G., Henríquez-Olavarrieta, S., Madrid, E., Parraga, M., Zepeda, A. B., & Moreno, R. D. (2012). The hypoxic testicle: Physiology and pathophysiology. *Oxidative Medicine and Cellular Longevity*, 2012, 1–15. <https://doi.org/10.1155/2012/929285>
- Risso, A., Pellegrino, F. J., Relling, A. E., & Corrada, Y. (2015). Effect of long-term fish oil supplementation on semen quality and serum testosterone concentrations in male dogs. *International Journal of Fertility and Sterility*, 10(2), 223–231. <https://doi.org/10.22074/ijfs.2016.4913>
- Rocha, A., da Cunha, I., Ederli, B., Albernaz, A., & Quirino, C. (2009). Effect of Daily Food Supplementation with Essential Fatty Acids on Canine Semen Quality. *Reproduction in Domestic Animals*, 44, 313–315. <https://doi.org/10.1111/j.1439-0531.2009.01438.x>
- Santos, M. C., Milani, C., Zucchini, P., Quirino, C. R., Romagnoli, S., & Cunha, I. C. N. (2019). Residual effect after salmon oil supplementation on semen quality and serum levels of testosterone in dogs. *Reproduction in Domestic Animals*, 54(10), 1393–1399. <https://doi.org/10.1111/rda.13530>
- Schwarz, C., Wirth, M., Gerischer, L., Grittner, U., Witte, A. V., Köbe, T., & Flöel, A. (2018). Effects of Omega-3 fatty acids on resting cerebral perfusion in patients with mild cognitive impairment: A randomized controlled trial. *The Journal of Prevention of Alzheimer's Disease*, 5(1), 26–30.
- Setchell, B., & Breed, W. (2006). Anatomy, vasculature, and innervation of the male reproductive tract. In *Knobil and Neill's physiology of reproduction*, 9780125154017, 0020063553 (pp. 771–825). USA: Elsevier. <https://doi.org/10.1016/B978-012515400-0/50022-1>
- Silva, E. G., Gonçalves, M. T. C., Pinto, S. C. C., Soares, D. M., Oliveira, R. A., Alves, F. R., Araújo, A. V. C., & Guerra, P. C. (2015). Análise quantitativa da ecogenicidade testicular pela técnica do histograma de ovinos da baixada ocidental maranhense. *Pesquisa Veterinária Brasileira*, 35(3), 297–303. <https://doi.org/10.1590/S0100-736X2015000300014>
- Singh, S., Arora, R. R., Singh, M., & Khosla, S. (2016). Eicosapentaenoic acid versus docosahexaenoic acid as options for vascular risk prevention: A fish story. *American Journal of Therapeutics*, 23(3), e905–e910. <https://doi.org/10.1097/MJT.0000000000000165>
- Sinn, N., & Howe, P. R. C. (2008). Mental health benefits of omega-3 fatty acids may be mediated by improvements in cerebral vascular function. *Bioscience Hypotheses*, 1, 103–108. <https://doi.org/10.1016/j.bihy.2008.02.003>
- Souza, M. B., Barbosa, C. C., England, G., Mota Filho, A. C., Sousa, C., de Carvalho, G. G., Silva, H., Pinto, J. N., Linhares, J., & Silva, L. (2015). Regional differences of testicular artery blood flow in post pubertal and pre-pubertal dogs. *BMC Veterinary Research*, 11(1), 47. <https://doi.org/10.1186/s12917-015-0363-3>
- Souza, M. B., Da Cunha Barbosa, C., Pereira, B. S., Monteiro, C. L. B., Pinto, J. N., Linhares, J. C. S., & Da Silva, L. D. M. (2014). Doppler velocimetric parameters of the testicular artery in healthy dogs. *Research in Veterinary Science*, 96(3), 533–536. <https://doi.org/10.1016/j.rvsc.2014.03.008>
- Souza, M. B., England, G. C. W., Mota Filho, A. C., Ackermann, C. L., Sousa, C. V. S., de Carvalho, G. G., Silva, H. V. R., Pinto, J. N., Linhares, J. C. S., Oba, E., & da Silva, L. D. M. (2015). Semen quality, testicular B-mode and Doppler ultrasound, and serum testosterone concentrations in dogs with established infertility. *Theriogenology*, 84(5), 805–810. <https://doi.org/10.1016/j.theriogenology.2015.05.015>
- Souza, M. B., Mota Filho, A. C., Sousa, C. V. S., Monteiro, C. L. B., Carvalho, G. G., Pinto, J. N., Linhares, J. C. S., & Silva, L. D. M. (2014). Triplex doppler evaluation of the testes in dogs of different sizes. *Pesquisa Veterinária Brasileira*, 34(11), 1135–1140. <https://doi.org/10.1590/S0100-736X2014001100017>
- Tomlinson, M., Jennings, A., Macrae, A., & Truysers, I. (2017). The value of trans-scrotal ultrasonography at bull breeding soundness evaluation (BBSE): The relationship between testicular parenchymal pixel intensity and semen quality. *Theriogenology*, 89, 169–177. <https://doi.org/10.1016/j.theriogenology.2016.10.020>
- Trautwein, L. G. C., Souza, A. K., Cardoso, G. S., da Costa Flaiban, K. K. M., de Oliveira Dearo, A. C., & Martins, M. I. M. (2020). Correlation of testicular artery Doppler velocimetry with kinetics and morphologic characteristics of epididymal sperm in dogs. *Reproduction in Domestic Animals*, 55(6), 720–725. <https://doi.org/10.1111/rda.13672>
- Vencato, J., Romagnoli, S., & Stelletta, C. (2014). Trans-scrotal ultrasonography and testicular fine-needle aspiration cytology in the evaluation of ram sperm production. *Small Ruminant Research*, 120(1), 112–115. <https://doi.org/10.1016/j.smallrumres.2014.05.005>
- Wang, Q., Liang, X., Wang, L., Lu, X., Huang, J., Cao, J., Li, H., & Gu, D. (2012). Effect of omega-3 fatty acids supplementation on endothelial function: A meta-analysis of randomized controlled trials. *Atherosclerosis*, 221(2), 536–543. <https://doi.org/10.1016/j.atherosclerosis.2012.01.006>
- Xin, W., Wei, W., & Li, X. (2012). Effect of fish oil supplementation on fasting vascular endothelial function in humans: A meta-analysis of randomized controlled trials. *PLoS One*, 7(9), e46028. <https://doi.org/10.1371/journal.pone.0046028>
- Zehr, K. R., & Walker, M. K. (2018). Omega-3 polyunsaturated fatty acids improve endothelial function in humans at risk for atherosclerosis: a review. *Prostaglandins Other Lipid Mediat*, 134, 131–140. <https://doi.org/10.1016/j.prostaglandins.2017.07.005>

How to cite this article: Santos MC, Milani C, Zucchini P, Quirino CR, Romagnoli S, da Cunha ICN. Salmon oil supplementation in dogs affects the blood flow of testicular arteries. *Reprod Dom Anim*. 2021;00:1–8. <https://doi.org/10.1111/rda.13886>